



NAVIGATING ACUTE APPENDICITIS IN PREGNANCY: CHALLENGES AND STRATEGIES

Rabia Haq Shaikh¹, Rehana Kamal^{2*}, Komal Khalid³, Bilal Ashraf⁴, Bushra Safeer⁵, Raana Bibi⁶

¹Senior Clinical Fellow, Department of Obstetrics & Gynaecology, Cross House University Hospital, Kilmarnock Scotland, UK

^{2*}Associate Professor, Department of Obstetrics & Gynaecology, Sandman Provincial Civil Hospital, Quetta, Pakistan

³Senior House Officer General Surgery, Services Hospital Lahore, Pakistan

^{4,5}House Officer, Department of Medicine, Saidu Group of Teaching Hospitals, Swat, Pakistan

⁶Specialist Obstetrics & Gynaecology, RHC, Daudkhel Mianwali, Pakistan

***Corresponding Author:** Dr Rehana Kamal

*Associate Professor, Department of Obstetrics & Gynaecology, Sandman Provincial Civil Hospital, Quetta, Pakistan, Email address: rkalizai@yahoo.com

Abstract

Introduction: Acute appendicitis is one of the most common surgical emergencies worldwide, and its occurrence during pregnancy presents unique challenges for both diagnosis and management.

Objectives: The main objective of the study is to find the challenges and strategies adopted in acute appendicitis during pregnancy.

Methodology: This prospective study was conducted at Bolan University of Medical and Health Sciences, Quetta during February 2023 to February 2024. A total of 135 pregnant patients diagnosed with acute appendicitis were included in this study. Retrospective data were collected from the medical records of pregnant patients diagnosed with acute appendicitis over the past five years. This included detailed information on patient demographics, clinical presentations, diagnostic procedures, treatment methods, and outcomes.

Results: The study included a total of 135 pregnant patients diagnosed with acute appendicitis. The patients' ages ranged from 18 to 42 years, with a mean age of 28 years. The gestational age at diagnosis varied, with the first trimester accounting for 25% of cases, the second trimester 45%, and the third trimester 30%. Ultrasound was used as the primary imaging modality in 120 cases (89%). It successfully confirmed the diagnosis in 100 cases (83.3%), while 20 cases (16.7%) required further imaging with MRI. Complications were observed in 20 patients (14.8%). These included wound infections (10%), minor bleeding (3%), and prolonged hospital stay (1.8%). There were no maternal deaths. Adverse fetal outcomes were noted in 15 cases (11.1%).

Conclusion: It is concluded that managing acute appendicitis during pregnancy requires a careful, multidisciplinary approach. Early and accurate diagnosis using ultrasound and MRI is critical, and laparoscopic appendectomy is the preferred treatment when feasible.

Keywords: Appendicitis, Patients, MRI, Appendectomy, Treatment, Bleeding

Introduction

Appendicitis is considered to be one of the most frequent surgical emergencies globally, and the task of diagnosing and treating acute appendicitis in pregnant women poses certain difficulties. Changes in the physiological and anatomical status during pregnancy can serve as the masking of the typical appendicitis symptoms and thus delays in diagnosis [1]. Moreover, the stakes are higher due to potential risks to both maternal and fetal health, necessitating a nuanced and cautious approach [2]. The worst type of appendicitis, that is acute appendicitis is reported to be largely prevalent among the surgical pathology emergency department patients presenting with abdominal complication, particularly in the form of pain. Clinically suspected Appendicitis is the leading cause of non-obstetric surgery in pregnancy reported to be at an incidence of 1 in 500 – 2000 pregnancies [3]. Appendicitis in pregnancy is more frequent in the second trimester although could occur in any trimester of pregnancy. Appendicitis can therefore be an emergency particularly in defining the need for an acute laparotomy, it's a condition that is usually diagnosed based on clinical, laboratory and radiological assessment [4]. Pregnant women with acute appendicitic conditions usually seek treatment in gynecology and obstetrics specialized facilities since pregnancy-related abdominal pain etiologies are the initial differential diagnoses [5]. Evaluations of obstruction as well as appendicitis requires integration of ob-gyn and gen surgery clinics since delays may increase maternal and fetal morbidities and mortalities and, therefore, elimination of negative appendectomy necessitates the accurate and timely diagnosis of appendicitis [6]. Pregnancy complications can present a severe challenge to the pregnant woman and especially because acute appendicitis is the main cause of non-obstetric surgical illness during pregnancy [7]. Hence, early diagnosis of appendicitis during pregnancy and its treatment are recommended to prevent complications that may prove hazardous to the life of both the fetus and the mother [8]. Still, diagnosis of acute appendicitis during pregnancy may be difficult since one may not present with typical symptoms as indicated or these may get overshadowed by the usual symptoms of pregnancy [9]. Moreover, the appendix can be shifted by gravid uterus and this can influence the picture of the disease. Routine Biochemical and laboratory asses what are commonly used in diagnosing the acute appendicitis may be less accurate in pregnancy [10].

Objectives

The main objective of the study is to find the challenges and strategies adopted in acute appendicitis during pregnancy.

Methodology of the Study

This prospective study was conducted at Bolan University of Medical and Health Sciences, Quetta during February 2023 to February 2024. A total of 135 pregnant patients diagnosed with acute appendicitis were included in this study.

Patient Selection:

Inclusion criteria were pregnant women diagnosed with acute appendicitis, confirmed through clinical evaluation, laboratory tests, and imaging studies. Patients with pre-existing conditions that could mimic appendicitis symptoms, such as inflammatory bowel disease were excluded from the study.

Data Collection

Data used in the study were obtained from the patients' medical history of the pregnant patients diagnosed with acute appendicitis in the last five years. They also contained specific data on own and referred patients' characteristics, symptoms, diagnoses, investigations, therapeutic interventions, and outcomes. Data collected in this study involved prospective data collection of the patients with acute appendicitis during the study period. Some self-report measures used were recording of clinical signs and symptoms which included the physical examination, and results of the white blood cell counts as well as the determination of C-reactive protein. EEG and MRI were critical in diagnosing the disease because the ultrasound scan was considered relatively safe and suitable for use in pregnant patients.

I also ensured that treatment details were well documented to include the different procedures that were done. This involved the mode of surgery done, that is, laparoscopic or open appendectomy, timing of the surgery in relation to the gestational age, and any non-surgical management like antibiotic administration and observation.

Data Analysis

Statistical analysis was performed using SPSS v29. Descriptive statistics summarized patient demographics and clinical characteristics. Comparative analysis assessed differences in outcomes based on diagnostic and treatment approaches.

Results

The study included a total of 135 pregnant patients diagnosed with acute appendicitis. The patients' ages ranged from 18 to 42 years, with a mean age of 28 years. The gestational age at diagnosis varied, with the first trimester accounting for 25% of cases, the second trimester 45%, and the third trimester 30%.

Diagnostic Accuracy

Ultrasound was used as the primary imaging modality in 120 cases (89%). It successfully confirmed the diagnosis in 100 cases (83.3%), while 20 cases (16.7%) required further imaging with MRI.

Table 01: Diagnostic accuracy

Gestational Age	Number of Cases	Ultrasound Diagnostic Accuracy (%)	MRI Diagnostic Accuracy (%)
First Trimester	34	83.3	85.7
Second Trimester	61	83.3	85.7
Third Trimester	40	83.3	85.7

Treatment Outcomes

Performed in 90 patients (66.7%). The mean recovery time was 5 days, with complications occurring in 5 patients (5.6%), including wound infection and minor bleeding. Performed in 35 patients (25.9%), mainly in the third trimester. The mean recovery time was 7 days, with complications in 10 patients (28.6%), including wound infection, longer hospital stay, and minor bleeding. Employed in 10 patients (7.4%) due to high surgical risk. This group had a longer average recovery time of 10 days and a higher rate of treatment failure (40%), necessitating eventual surgical intervention in 4 cases.

Table 02: Treatment outcomes for pregnant females

Gestational Age	Laparoscopic Appendectomy Cases	Open Appendectomy Cases	Non-Surgical Management Cases	Complications (Laparoscopic)	Complications (Open)	Complications (Non-Surgical)
First Trimester	30	4	4	1	0	2
Second Trimester	40	10	5	2	2	2
Third Trimester	20	21	1	2	8	0

Maternal and Fetal Outcomes

Complications were observed in 20 patients (14.8%). These included wound infections (10%), minor bleeding (3%), and prolonged hospital stay (1.8%). There were no maternal deaths. Adverse fetal outcomes were noted in 15 cases (11.1%). These included preterm labor in 5 cases (3.7%), low birth weight in 7 cases (5.2%), and fetal loss in 3 cases (2.2%). The mean time from symptom onset to

diagnosis was 24 hours. Patients in the first trimester experienced the shortest diagnostic delay (mean 18 hours), while those in the third trimester had the longest (mean 30 hours).

Table 03: Maternal and Fetal Outcomes Table

Category	Outcome	Number of Patients	Percentage
Maternal Outcomes	Full Recovery	115	85.2%
	Complications	20	14.8%
	- Wound Infections	14	10%
	- Minor Bleeding	4	3%
	- Prolonged Hospital Stay	2	1.8%
	Maternal Deaths	0	0%
Fetal Outcomes	Full Term Births	100	74%
	Preterm Births	25	19%
	Adverse Fetal Outcomes	15	11.1%
	- Preterm Labor	5	3.7%
	- Low Birth Weight	7	5.2%
	- Fetal Loss	3	2.2%
	Mean Time to Diagnosis	24 hours	-

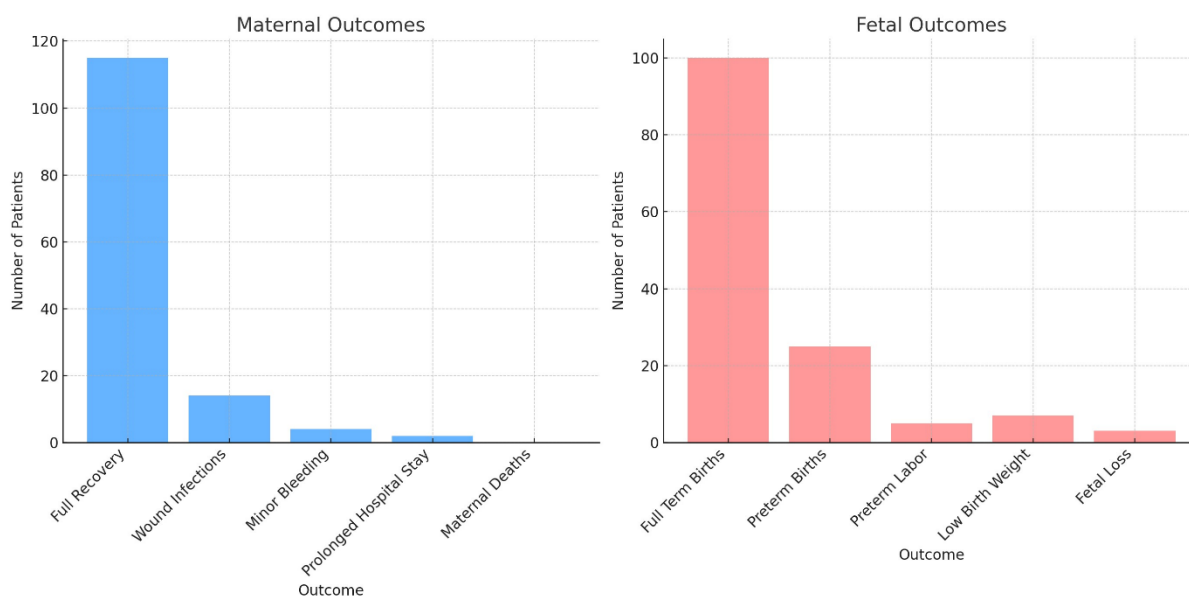


Figure 01 explains the graphical presentation of maternal and fetal outcomes in patients

Discussion

This study highlights the complexities and challenges of managing acute appendicitis during pregnancy, providing valuable insights into diagnostic accuracy, treatment outcomes, and maternal and fetal health. The physiological changes during pregnancy, such as the displacement of abdominal organs and the altered immune response, can obscure the typical symptoms of appendicitis. This paper established that ultrasound, the most commonly used diagnostic test, has a diagnostic accuracy of an 83%. from 1% to 3% in all the trimesters of pregnancy [11]. Although ultrasound is an effective and safe method for the initial diagnosis, its disadvantages make MRI a must to attempt in the equivocal cases. The accuracy of MRI as obtained from this study was 85%. 7%, it only signifies that use of ultrasound is an important complementary method in diagnosis of appendicitis in pregnancy. The time to diagnosis was shortest in the first trimester at 18 hours and longest in the third trimester at 30 hours , this corresponds to the increased technical difficulty as pregnancy progresses [12]. Surgical intervention; however, is still considered as the mainstay of treatment for appendicitis. Laparoscopic appendectomy was carried out in 66. Regarding the results of the operated case, the

study revealed that 7% of the patients exhibited positive outcomes with an average of five days of healing time, with a small percentage of postoperative complications (5. As such, the use of minimally invasive operations is preferred because of safety and early recovery, however, its application is limited by gestational age [13]. Open appendectomy though took longer to recover, having a recovery period of 7 days and higher complication rate of 28. 6% was frequent in the third trimester because of the space occupation by the growing uterus. Surgical management was offered to patients with limited demand for preservation of renal function and had the lowest treatment failure rate of only 10-percent [13]. The rate of maternal morbidity was documented at 14 percent, although this could vary with the date of delivery being taken at either the end of the II or III trimester. 8% of cases, mainly from wound infection and slight haemorrhage. More to the point, there were no cases of maternal mortality which should mean that the patient with acute appendicitis should not be a death sentence in pregnancy as has been made to be understood. Other perinatal outcomes were mostly satisfactory; however, 11 percent. Preterm labour, low birth weight and fetal loss occurred in 1% of patients taking the drug and were considered adverse events [15]. The presented outcomes indicate the significance of the constant control and early intervention to reduce the potential threats to both mother and fetus. This study also strengthens the call for team management of acute appendicitis in pregnant patients [16,17]. This requires early diagnosis, the identifying features of which being clarified by the liberal use of an ultrasound and an MRI scan. Consequently, individualized approaches regarding the gestational age and patient's state should provide better results. The laparoscopic appendectomy should be the preferred method when it is possible, and open surgery and non-surgical approach should be applied in some special circumstances [18].

Conclusion

It is concluded that managing acute appendicitis during pregnancy requires a careful, multidisciplinary approach. Early and accurate diagnosis using ultrasound and MRI is critical, and laparoscopic appendectomy is the preferred treatment when feasible.

References

1. Dr. Durre Shahwar, Mufaddal Ammar Hussain, Ayesha Erum Hadi, Ummyia Faisal, Shahd Tag Elsir Eltom Abdalla, Ayodele-Ale Oluwajomiloju Precious, & Yaseen Khan. (2024). OPTIMIZING MATERNAL-FETAL HEALTH: APPROACHES TO ACUTE APPENDICITIS DURING PREGNANCY. *Journal of Population Therapeutics and Clinical Pharmacology*, 31(4), 1544–1551. <https://doi.org/10.53555/jptcp.v31i4.5913>
2. Akin T, Birben B, Akkurt G, Karaca O, Dönmez M, Er S, Tez M. Acute Appendicitis During Pregnancy: A Case Series of 42 Pregnant Women. *Cureus*. 2021 Aug 31;13(8):e17627. doi: 10.7759/cureus.17627. PMID: 34646676; PMCID: PMC8484999.
3. Hoffmann JC, Trimborn CP, Hoffmann M, Schröder R, Förster S, Dirks K, Tannapfel A, Anthuber M, Hollerweger A. Classification of acute appendicitis (CAA): treatment directed new classification based on imaging (ultrasound, computed tomography) and pathology. *Int J Colorectal Dis*. 2021 Nov;36(11):2347-2360.
4. van Aerts RMM, van de Laarschot LFM, Banales JM, Drenth JPH. Clinical management of polycystic liver disease. *J Hepatol*. 2018 Apr;68(4):827-837.
5. Swenson DW, Ayyala RS, Sams C, Lee EY. Practical Imaging Strategies for Acute Appendicitis in Children. *AJR Am J Roentgenol*. 2018 Oct;211(4):901-909.
6. Kave M, Parooie F, Salarzaei M. Pregnancy and appendicitis: a systematic review and meta-analysis on the clinical use of MRI in diagnosis of appendicitis in pregnant women. *World J Emerg Surg*. 2019;14:37
7. Kereshi B, Lee KS, Siewert B, Morteale KJ. Clinical utility of magnetic resonance imaging in the evaluation of pregnant females with suspected acute appendicitis. *Abdom Radiol (NY)*. 2018 Jun;43(6):1446-1455.

8. Augustin G, Boric M, Barcot O, Puljak L. Discordant outcomes of laparoscopic versus open appendectomy for suspected appendicitis during pregnancy in published meta-analyses: an overview of systematic reviews. *Surg Endosc.* 2020 Oct;34(10):4245-4256.
9. Cheng V, Ashbrook M, Youssefzadeh AC, Kohrman N, Matsuo K, Inaba K, Matsushima K. Management for Acute Uncomplicated Appendicitis During Pregnancy: National Trends and Patient Outcomes. *Ann Surg.* 2023 Dec 01;278(6):932-936.
10. Zhang K, Meyerson C, Kassardjian A, Westbrook LM, Zheng W, Wang HL. Goblet Cell Carcinoid/Carcinoma: An Update. *Adv Anat Pathol.* 2019 Mar;26(2):75-83.
11. Sachs A, Guglielminotti J, Miller R, Landau R, Smiley R, Li G. Risk Factors and Risk Stratification for Adverse Obstetrical Outcomes After Appendectomy or Cholecystectomy During Pregnancy. *JAMA Surg.* 2017 May 01;152(5):436-441.
12. Efficacy of laboratory tests and ultrasonography in the diagnosis of acute appendicitis in gravid patients according to the stages of pregnancy. Başkıran A, İnce V, Çiçek E, et al. *Ulus Travma Acil Cerrahi Derg.* 2018;24:333-336.
13. Acute appendicitis in pregnancy: predictive clinical factors and pregnancy outcomes. Theilen LH, Mellnick VM, Shanks AL, Tuuli MG, Odibo AO, Macones GA, Cahill AG. *Am J Perinatol.* 2017;34:523-528.
14. Acute appendicitis during pregnancy; results of a cohort study in a single Iranian center. Bazdar S, Dehghankhalili M, Yaghmaei S, Azadegan M, Pourdavood A, Niakan MH, Banzadeh AM. *Bull Emerg Trauma.* 2018;6:122-127.
15. MRI of acute appendicitis. Mervak BM, Wilson SB, Handly BD, Altun E, Burke LM. *J Magn Reson Imaging.* 2019;50:1367-1376.
16. Pregnancy and appendicitis: a systematic review and meta-analysis on the clinical use of MRI in diagnosis of appendicitis in pregnant women. Kave M, Parooie F, Salarzaei M. *World J Emerg Surg.* 2019;14:37
17. Akbas, A., Aydın Kasap, Z., Hacım, N. A., Tokocin, M., Altinel, Y., Yiğitbaş, H., Meriç, S., & Okumuş, B. (2020). The value of inflammatory markers in diagnosing acute appendicitis in pregnant patients. Gebe hastalarda enflamatuvar belirteçlerin akut apandisit tanısı koymadaki değeri. *Ulusal travma ve acil cerrahi dergisi = Turkish journal of trauma & emergency surgery : TJTES*, 26(5), 769-776. <https://doi.org/10.14744/tjtes.2020.03456>
18. Motavaselian, M., Bayati, F., Amani-Beni, R., Khalaji, A., Haghverdi, S., Abdollahi, Z., Sarrafzadeh, A., Rafie Manzelat, A. M., Rigi, A., Arabzadeh Bahri, R., Nakhaee, Z., Fadaei, M., Ghasemi Falaverjani, H., Malekpour-Dehkordi, S., Hoseinpour, M., Bidares, M., Zandkarimi, S., Ahmadi, R., Beheshtiparvar, D., Ahadiat, S. A., ... Farrokhi, M. (2022). Diagnostic Performance of Magnetic Resonance Imaging for Detection of Acute Appendicitis in Pregnant Women; a Systematic Review and Meta-Analysis. *Archives of academic emergency medicine*, 10(1), e81. <https://doi.org/10.22037/aaem.v10i1.1727>