



## A PROSPECTIVE OBSERVATION STUDY OF ASSOCIATED CAUSES OF SINGLE UMBILICAL ARTERY AND ITS ADVERSE PREGNANCY OUTCOMES

Dr. Renu Yadav<sup>1</sup>\*, Dr. Deepika Verma

<sup>1</sup>Pg 3rd Year Resident, Index medical college and research center indore mp,  
Email.id- renuyadav.456@rediffmail.com

<sup>2</sup>Professor, Index medical college and research center indore mp

**\*Corresponding Author:** Dr. Renu Yadav

\*Pg 3rd Year Resident, Index medical college and research center indore mp,  
Email.id- renuyadav.456@rediffmail.com

---

### ABSTRACT-

**AIM AND OBJECTIVE-** Single umbilical artery is a abnormal condition of the umbilical cord in which one artery is missing . To evaluation of risk factor and associated causes and associated various maternal and neonatal outcomes related to single umbilical artery.

**METHOD AND MATERIAL-** Women were their 2<sup>nd</sup> and 3<sup>rd</sup> trimester, as well as their fetuses were selected regardless of age, ethnicity or socio-economic status.all records were reviewed to compare information on maternal complications, twinning,gestational age, birth weight, maternal age and congenital anomalies, pregnancy outcomes of cases were recorded. There was sample size 32 and study was a prospective observational study from sept. 2019to 30 sept 2022 in index medical college indore ,(m.P)

**RESULT-** There were 32 cases of SUA with and without established anomaly diagnosed antenatally. Gestational age ranged between 132-289 days. Median maternal age was 28 (19-36) years. Gravida was 1-3 . There were 20 pregnancies with premature rupture of membranes. Intrauterine cardiac anomaly in 2 fetuses, trisomy 13 in one case and another had trisomy 18 , and anencephaly was present in 8 fetuses, cryptorchidism had 4 fetuses, hypothyroidism were detected in 2 fetuses. 22 cases were delivered by normal vaginal delivery , 10 cases by caesarean section . 10 cases were diagnosed with oligohydramnios, 22 cases with polyhydramnios.

**CONCLUSION-** identification of single artery is important for prenatal diagnosis of congenital anomalies and aneuploidy. According to our study finding , the risk of intrauterine growth restriction is increased and repeated ultrasound examination with doppler assessment and testing for fetal wellbeing may be necessary in later week of gestation. Early intra partum surveillance with isolated single umbilical artery may improve pregnancy outcomes.

**INTRODUCTION-** SUA is a malformation of the umbilical cord where only one artery instead of two is present, or may be associated with other birth defects.

The pathogenesis of an SUA is thought to be secondary to vessel atrophy of a previously normal cord in the mid trimester<sup>1</sup>. umbilical cord forms between 13 and 38 days after conception . some report that dis umbilical abnormality can be observed as soon as at 13 weeks.there are the three theories to explain how a SUA may form during development . The first is that a primary aganglionosis

of one umbilical artery results in a SUA. Another theory attributes the phenomenon to a secondary atrophy or atresia of a previously normal umbilical artery. A third theory describes a persistence of the original allantoic artery of the body stalk as an explanation for SUA<sup>2-3</sup>. incidence of SUA in 1.5% in spontaneous abortuses, 7% of pregnancy that were terminated because of a serious malformation, 0.2% to 1.6% of euploid fetuses who underwent prenatal ultrasound examination<sup>2</sup>. The reported incidence of SUA varies depending on the method used to identify its occurrence, being highest in abortuses and autopsies and relatively low on ultrasound and in term neonates<sup>4</sup>. The SUA incidence is 3–4 times higher in multiple pregnancies than in singleton pregnancy<sup>5</sup>. The most widely accepted causes for this anomaly are primary agenesis and/or late thrombotic atrophy<sup>6</sup>. Fetuses with a single umbilical artery has significantly more chromosomal (10.3%) and congenital anomalies (2.7%) than those with two umbilical arteries. incidence is increased in women with diabetes, hypertension, aph, oligohydroamnios, and polyhydramnios. In previous studies; many risk factors have been suggested, including maternal smoking status, multiple gestations, ethnicity, maternal age, and multiparity<sup>7</sup>

It has also been indicated in some studies that the risks of some adverse pregnancy outcomes; such as hypertensive disorders, intrauterine growth restriction, preterm delivery, and low birth weight in pregnancy; could be augmented in cases with a single umbilical artery<sup>8</sup>. SUAs have been associated with fetal aneuploidy, premature delivery, stillbirths, low birth weight, and multiple congenital anomalies (including cardiac, renal, and musculoskeletal abnormality). The introduction of prenatal ultrasound has made the assessment of the umbilical cord and prenatal diagnosis of SUA possible<sup>9-10</sup>.

**AIM AND OBJECTIVE-** 1. To evaluate the maternal and fetal outcomes in the case of single umbilical artery 2. To identify risk factor for fetuses and neonates with single umbilical artery 3. To assess whether there is an increased risk for complications during pregnancy, labour, and delivery, and for perinatal morbidity and mortality

**METHOD AND MATERIAL-** my study was prospective observational study in department of obstetric and gynaecology department of index medical college, hospital and research centre indore, (M.P) from July 2019 to June 2021 (duration -1 year). The women in 2<sup>nd</sup> and 3<sup>rd</sup> trimester with USG diagnosis of single umbilical artery in antenatal period, as well as their fetuses, were selected regardless of age, ethnicity or socioeconomic status, all records were reviewed to compare information on maternal complications, twinning, gestational age, birth weight, maternal age, mode of delivery, fetal gender and congenital anomalies. the pregnancy outcomes of cases were recorded, and the number of anomalies in each category was tabulated. these women had an ultrasound performed during their pregnancy. however, all available ultrasound data were reviewed. when clinically indicated, placental samples, or neonatal blood specimens were analyzed for chromosomal abnormalities through standard karyotyping procedure.

**INCLUSION CRITERIA-**

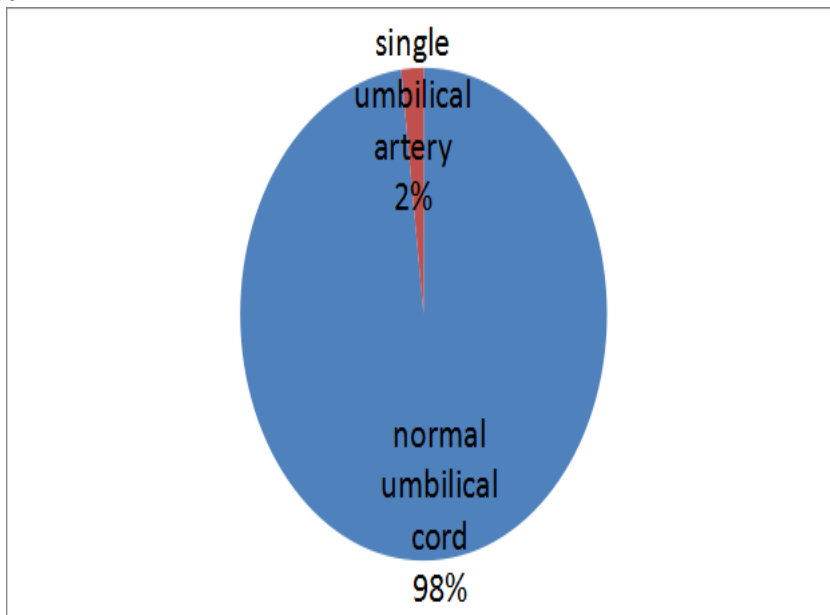
1. Women who had h/o women with diabetes, epilepsy, APH, oligohydroamnios, polyhydramnios
2. Women who had antenatal diagnostic USG scan with single umbilical artery
3. Women who had previous pregnancy h/o IUGR

**EXCLUSION CRITERIA-** Pregnant women who had normal umbilical cord in its obstetric ultrasound scan.

**RESULT-** There were 32 cases of SUA with and without established anomaly diagnosed antenatally. Gestational age ranged between 132-289 days. Median maternal age was 28 (19-36) years. Gravida was 1-3. There were 20 pregnancies with premature rupture of membranes.

Intrauterine cardiac anomaly in 2 fetuses, trisomy 13 in one case and another had trisomy 18, and anencephaly was present in 8 fetuses, cryptorchidism had 4 fetuses, hypothyroidism were detected in 2 fetuses. 22 cases were delivered by normal vaginal delivery, 10 cases by caesarean section. 10 cases were diagnosed with oligohydramnios, 22 cases with polyhydramnios. 5 cases had invitrofertilization. Male gender was 70%

**Overall incidence**



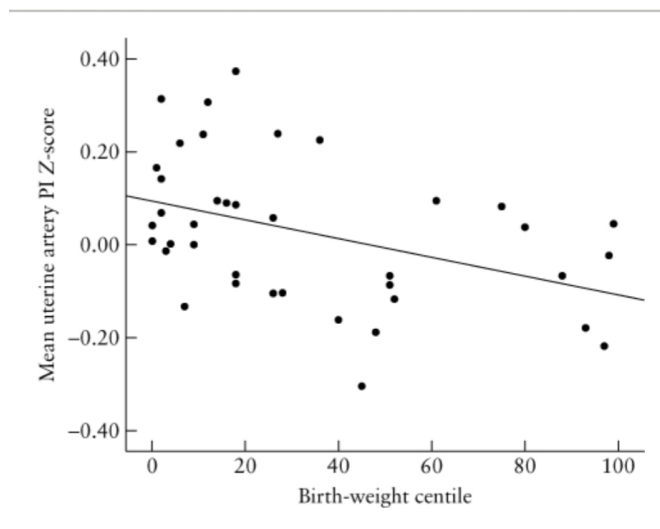
**DEMOGRAPHIC CHARACTERISTICS**

Demographic characteristics	No. (32)
Maternal age	28 (20-38)
Gestational age in day	230(132-289)
gravida	1-3
oligohydramnios	10
IUGR	22
Anencephaly	8
Intrauterine death	4

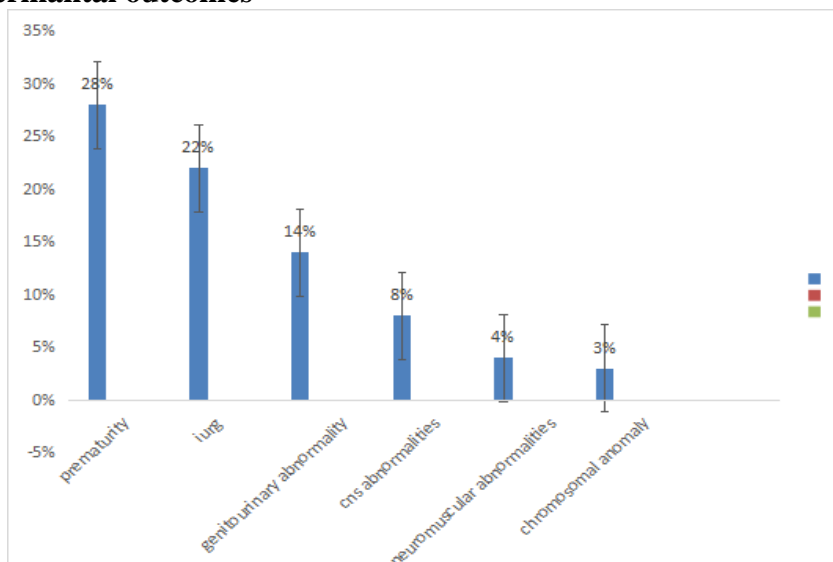
**Maternal outcomes-**

Pre-existing diabetes	10%
hypertension	12%
oligohydramnios	31.22%
polyhydramnios	6.25%
Placental abnormalities	62.5%

## SIGNIFICANT CORRELATION MEAN UTERINE ARTERY AND FETAL BIRTH WEIGHT



## Prevalence of perinatal outcomes



**DISCUSSION-** Normally, there are two arteries and one vein in the umbilical cord. When one of the umbilical arteries is missing, this a condition referred to as “single umbilical artery” (SUA). Primary agenesis of one umbilical artery, persistence of the original single allantoic artery of the body stalk, or later thrombotic atrophy of one umbilical artery are the most widely accepted underlying explanations that would result in SUA. Development of a single umbilical artery is associated with primary agenesis of umbilical arteries, or atrophy or atresia of an existing artery. Ultrasonography is important in diagnosis. In normal circumstances, a finding resembling a “Mickey Mouse” image is displayed. We do not see this image in SUA. Usually a horizontal section view of the umbilical cord obtained 3cm distant from the location where the cord leaves the placenta, should display the 3 vessels. Normally the arterial diameters are equal and are less than the half of the vein diameter. In these cases; the artery diameter is wider than the vein radius. Persutte et al.<sup>11</sup> have indicated that a transverse umbilical arterial diameter of > 4 mm in the 20th - 36th pregnancy weeks is an important indicator of SUA. Another method is; while an investigation by color Doppler scanning of the fetal pelvis provides an image of two separate arteries navigating from both sides of the bladder, in case of SUA there is only one artery developing on one side of the bladder. The cases we have included in our study were cases detected through detailed ultrasonography.

the absence of umbilical artery was diagnosed by examining the cord after the delivery. diagnosis can now be made even in the first trimester with the help of ultrasonography.

Detection of SUA by ultrasonography is affected by many factors; i.e., length of the cord, a gyros shape, the experience of the doctor, thickness of the skin, the position of the baby, and quality of the device. In our study; 26 cases detected by detailed ultrasonography were included in the study. We believe that the reason for detecting a low number of cases is related to the fact that the detailed ultrasonography is performed during the second trimester perinatal examinations, whereas they could be detected even in the first trimester. Fetal echo, which requires high level specialization in our clinic, has not been performed in all cases. Of the cases which underwent the echo procedure; intrauterine fetal anomaly was detected in two (6.25%). It has been reported that 15-20% of SUA cases are associated with cardiovascular anomalies. Prefumo et al.<sup>12</sup> have displayed that between selected and unselected groups of fetuses with an SUA, and consistent with the presence or absence of extra cardiac abnormalities; the prevalence of congenital heart disease (CHD) shows a substantial difference. They suggest that, if an extended basic cardiac scan, including four-chamber and outflow tract views have been performed, referral for specialist fetal echocardiography is not necessary unless a cardiac abnormality is suspected.

In cases that are diagnosed with SUA in the prenatal phase, the existence of additional congenital malformations is checked through detailed ultrasonography. If they exist; it has been reported that invasive interventions for chromosomal analysis are required. In isolated cases with no additional structural anomalies; chromosomal anomalies are not expected. Thus karyotype identification is not recommended in isolated cases. Chromosomal anomalies; particularly trisomy 13 and trisomy 18, can be seen in approximately in 50% of cases with additional anomalies.

the SUA is more frequent in assisted reproductive technique pregnancies than normal developing pregnancies. There may be an association between the use of progesterone and SUA development, due to atrophic and apoptotic influences of progesterone, but there is a need for further investigation of this area. In our study, 5 cases were determined as IVF pregnancies.

in our study, determined trisomy 13 in two case, and trisomy 18 in another one. Familial predisposition does not exist in single umbilical artery cases. Musculoskeletal system anomalies, urogenital, cardiovascular, gastrointestinal system, vertebral, crania-neural system, ophthalmic anomalies, diaphragmatic hernia, hydrops fetalis are among the other anomalies associated with SUA. Anomalies related to SUA may concern every system in the body. In our study; we have detected a descending aorta hypoplasia in one patient, thyroid hypoplasia in another and; undescended testicles in two cases.

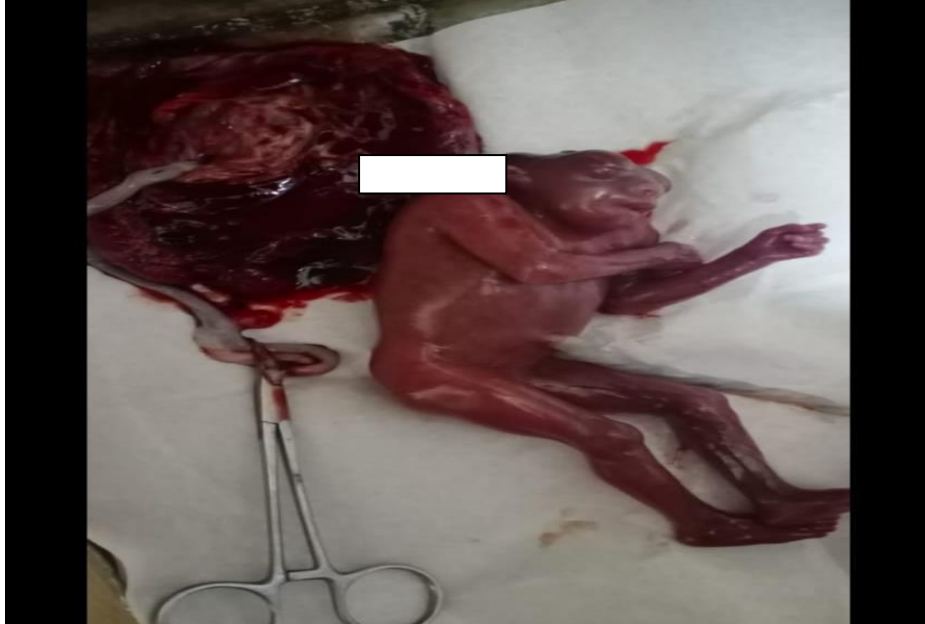Chang et al<sup>13</sup> suggested that fetuses with a prenatal diagnosis of SUA and other developmental abnormalities need undergo prenatal chromosomal examination. For fetuses with uncomplicated SUA, careful ultrasound examination is necessary to avoid missed diagnosis of potential congenital abnormalities. In accordance with Chang et al, we suggest that when the single umbilical artery is an isolated ultrasonography finding, neonates will still have a possibility of having minor problems such as cryptorchidism.

In the presence of SUA; a normal fetus receives less oxygen. Predanic M et al<sup>14</sup> have not discovered a significant correlation between the single umbilical artery cases and birth weight. The birth weights in our study also were determined as low to normal, with a median of 2089 grams (1345–2509 grams) 22 cases were having IUGR, due to prematurity, the birth weight has been low.

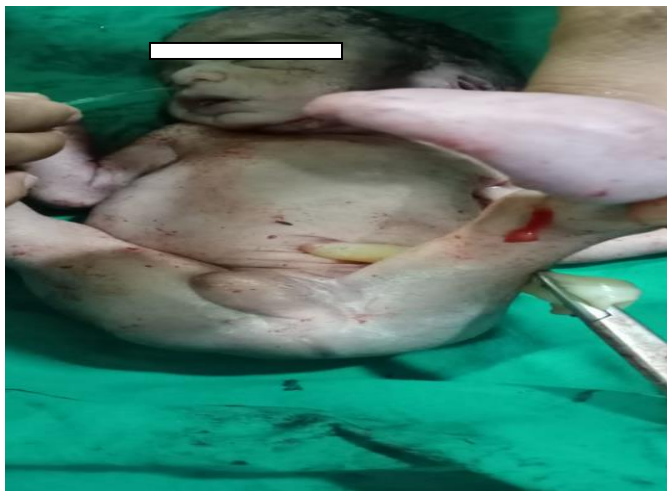
In our study shows correlation has been determined between SGA fetuses and SUA in our cases. Small for gestational age (SGA), which is defined as an infant that does not display any abnormal parameters on Doppler studies and has a weight below the 10th percentile because of local curves<sup>15</sup>. The incidence of small for gestational age (SGA) fetuses and hypertensive disorders in pregnancy was found to be significantly higher in cases with an isolated SUA<sup>16</sup>

Burnshetin et al<sup>17</sup> have shown that growth retardation, polyhydramnios, oligohydramnios and caesarean rates increase in fetuses with SUA. In our cases; 22 patients had normal vaginal deliveries,

10 patients were applied cesarean section; a further 10 cases were diagnosed with oligohydramnios, 22 with polyhydramnios. Although a majority of previous studies have indicated that in cases with an isolated single umbilical artery, cesarean rates are higher due to non-reassuring fetal heart trace, while other studies have failed to display any difference .

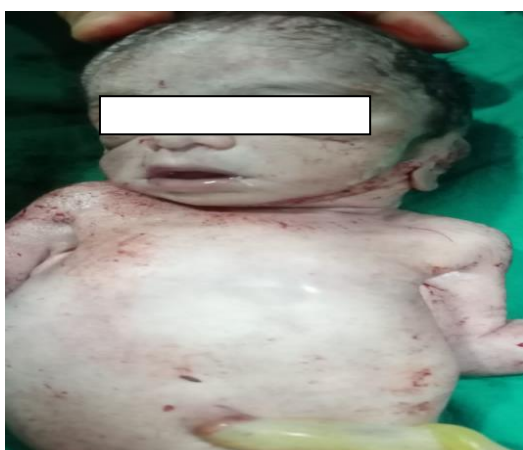
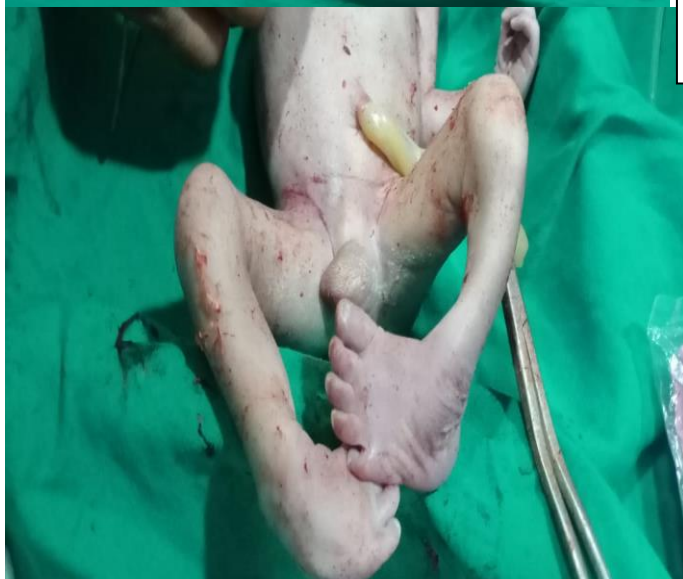
case no. 1 , 28yr old with 19wk+1 day With polyhydramnion , at 19wkFetal oucome- anencephaly, SUA, With congenital heart disease



CASE no.x ,30 year old ,G2 A1 with 36week +6day of gestation had delivered by caesarian section .Baby had small ear, strawberry shape head, choroid plexus cyst ,clenched fingers, Right aortic arch, no anal spincter, no urethra , all extremities are longer, club foot some oesophageal anomaly ,Single umbilical artery suggestive by EDWARD SYNDROME

**(SUA ASSOCIATED WITH CHROMOSOMAL ABNORMALITIES( CHROMOSOMAL 18 TRISOMY)**



Case y- ,23 year old ,21wk+4d period of gastation,pregnancy Outcome is preterm baby,polyHydramnios, with omphalocele with bilateral ventriculomegaly with IUGR & SUA

**CONCLUSION-**Fetuses and neonates with single umbilical artery are at increased risk for adverse outcomes. Identification of SUA is important for prenatal diagnosis of congenital anomalies and aneuploidy. According to study finding , the risk of intrauterine growth restriction is increased and repeated ultrasound examination with doppler assessment and testing for fetal wellbeing may be necessary in later week of gestation.increased surveillance with SUA may improve pregnancy outcomes

The radiologist and obstetrics & gynecology specialists who perform this procedure, should take note that the umbilical cord should at least be examined for quantitative anomalies. Counseling of the parents should be done properly. In pregnancies which have an isolated single umbilical artery complication, a strict monitoring for preterm birth seems to be unfeasible. Larger sample sized prospective studies would be beneficial.

#### REFERENCES-

1. Benirschke, K and Brown, W.H. A vascular anomaly of the umbilical cord: the absence of one artery in the umbilical cord of normal and abnormal fetuses. *Obstetrics and Gynecology* 6, 399-404. 1955.
2. Perutte WH, Hobbins J. Single umbilical artery; A clinical enigma in modern prenatal diagnosis. *ultrasound obstet gynecol* 1995; 6;216-229
3. Moore KL, Persaud TVN. The placenta and fetal membranes, in ; Moore kL, Persaud tvn, editors. *The Developing human; clinically oriented embryology*, 6<sup>th</sup> ed. Philadelphia; W.B. Saunders, 1998; 129-162
4. Remore R, Pulu G, Jeanty P, Ghidini A, Hobbins JC, Editors. *Prenatal diagnosis of congenital anomalies*. Norwalk; Appleton and Lange, 1998.2.
5. Volpe G, et al. ["Isolated" single umbilical artery: incidence, cytogenetic abnormalities, malformation and perinatal outcome] *Minerva Ginecol*. 2005;57:189–198. [[PubMed](#)] [[Google Scholar](#)]
6. Gornall AS, Kurinczuk JJ, Konje JC. Antenatal detection of a single umbilical artery: does it matter? *Prenat Diagn*. 2003;23:117–123. doi: 10.1002/pd.540. [[PubMed](#)] [[CrossRef](#)] [[Google Scholar](#)]
7. Jones TB, Sorokin Y, Bhatia R, Zador IE, Bottoms SF. Single umbilical artery: accurate diagnosis? *Am J Obstet Gynecol* 1993; 169: 538
8. Khalil MI, Sagr ER, Elrifaei RM, Abdelbasit OB, Halouly TA. Outcomes of an isolated single umbilical artery in singleton pregnancy: a large study from the Middle East and Gulf region. *Eur J Obstet Gynecol Reprod Biol* 2013; 171: 27780.
9. Chow JS, Benson CBD, Doubilet PM. Frequency and nature of structural anomalies in fetuses with single umbilical arteries. *J Ultrasound Med*. 1998; 17:7658-
10. Martínez-Payo CG, Aitero AT, Amarit IG, García-Espantaleón MI, Iglesias Goy E. Perinatal results following the prenatal ultrasound diagnosis of single umbilical artery. *Acta Obstet Gynecol Scand* 2005;84:1068
11. Persutte WH, Hobbins J. Single umbilical artery: a clinical enigma in modern prenatal diagnosis. *Ultrasound Obstet Gynecol* 1995;6:216-29.
12. Prefumo F, Guven MA, Carvalho JS. Single umbilical artery and congenital heart disease in selected and unselected populations. *Ultrasound Obstet Gynecol* 2010;35:552–5.12
13. Chang Q, Chen C, Zhong M, Qiu Y, Xiao C, Huang Q, Yu Y. Prenatal diagnosis of single umbilical artery: implications for chromosomal abnormalities and neonatal outcome. *Nan Fang Yi Ke Da Xue Xue Bao* 2013;33:451-3
14. Predanic M, Perni SC, Friedman A, Chervenak FA, Chasen ST. Fetal growth assessment and neonatal birth weight in fetuses with an isolated single umbilical artery. *Obstet Gynecol*. 2005;105:1093-7
15. Salihoglu O, Karatekin G, Uslu S, Can E, Baksu B, Nuhoglu A. New intrauterine growth percentiles: a hospital based study in Istanbul, Turkey. *J Pak Med Assoc*. 2012;62:1070–74
16. Tulek F, Kahraman A, Taskın S, Özkavukçu E, Söylemez F. Determination of risk factors and perinatal outcomes of singleton pregnancies complicated by isolated single umbilical artery in Turkish population. *J Turk Ger Gynecol Assoc*. 2015;16:21
17. Burshtein S, Levy A, Holcberg G, Zlotnik A, Sheiner E. Is single umbilical artery an independent risk factor for perinatal mortality? *Arch gynecol obstet*. 2011;283(2);191-4