



ACCIDENTAL DEATH DUE TO HAND SANITIZER POISONING - A CASE SERIES.

Dr. Sangita Chaurasia¹, Dr. Saagar Singh², Dr. Rajneesh Kumar Pandey³, Dr. Mrityunjay Singh Tomar^{4*}

¹Assistant Professor, Department of Forensic Medicine and Toxicology, Gandhi Medical College, Bhopal, MP, India, sangitachaurasia29@gmail.com

²Junior Resident, Department of Forensic Medicine and Toxicology, Gandhi Medical College, Bhopal, MP, India, sukumar.singh4@gmail.com

³Assistant Professor, Department of Forensic Medicine and Toxicology, Shyam Shah Medical College, Rewa, MP, India., edu.rkp@gmail.com

^{4*}Junior Resident, Department of Forensic Medicine and Toxicology, Gandhi Medical College, Bhopal, MP, India, mrityunjaysinghtomar@gmail.com

Corresponding Author: Dr. Mrityunjay Singh Tomar

*Junior Resident, Department of Forensic Medicine and Toxicology, Gandhi Medical College, Bhopal, MP, India, mrityunjaysinghtomar@gmail.com

Abstract:

Hand sanitizer is a liquid containing either ethyl alcohol or isopropyl alcohol. During the COVID-19 pandemic, due to an unprecedented lockdown, and non-availability of consumable alcohol, some alcohol-addicted people started consuming hand sanitizer, which was easily available to the common masses. Here we present six accidental deaths brought for autopsy, with a history of acute over-consumption of hand sanitizer. All cases had a history of chronic alcoholism and consumption of hand sanitizer. They consumed an unknown amount of hand sanitizer containing 70% v/v ethanol per 100 ml. A clinical work-up and medico-legal autopsy combined with the preservation of viscera samples for toxicological analysis and tissue samples for histopathology were performed to determine the cause of death. Gross autopsy findings, positive Forensic Science Laboratory toxicology report, and histopathological findings confirmed death due to multi-organ dysfunction caused by acute hand sanitizer poisoning. History, circumstantial evidence, and crime scene findings confirmed the accidental manner of death. The present cases shed light on an emerging problem of hand sanitizer poisoning in India among alcohol-addicted people, particularly those who belong to the lower socio-economic strata.

Keywords: Accidental death, Autopsy, Forensic pathology, Hand sanitizer poisoning.

Introduction

Hand sanitizer is an alcohol-based product typically containing some combinations of ethyl alcohol, isopropyl alcohol, or n-propanol in the form of a liquid, gel, or foam used to disinfect hands. Most healthcare settings prefer alcohol-based hand sanitizers over hand washing with soap and water. A combination containing 60 to 95 percent ethyl alcohol is most effective, and its activity as a disinfectant and antimicrobial agent is both immediate and persistent. ^[1] The WHO recommends a

concentration of 80% v/v ethyl alcohol and 75% v/v isopropyl alcohol to meet recognized standards for microbicidal efficacy in hand sanitizer. [2]

According to the American Association of poison control Centers; there were nearly 12,000 cases of hand sanitizer ingestion in 2006. [3] People with chronic alcoholism may attempt to consume hand sanitizer in desperation when traditional alcoholic beverages are unavailable, or personal access to them is restricted by force or law. There have been reported incidents of people drinking the gel in prisons and hospitals to become intoxicated. [4-6]

Since the advent of COVID-19, there has been an increase in awareness regarding hand hygiene by using hand sanitizer. To fight the COVID pandemic, the government started to distribute hand sanitizer free of cost among the common masses. According to a study conducted in Italy, there was a possible misuse of disinfectant products during the SARS-CoV-2 pandemic, underlying the effects of home isolation on mental health and unintentional toxic exposures. [7] During the COVID-19 pandemic in New Mexico, alcoholics were severely injured by drinking hand sanitizer containing methyl alcohol. [8-10] Several reports described the ingestion of hand sanitizers as a surrogate for potable alcohol by patients with hand sanitizer products containing methanol. Many alcohol-based hand sanitizer formulations contained methanol during the 2020 pandemic. Exposure to these products led to increased harm and death. [11] To the best of our knowledge, only a few reports are available regarding death from hand sanitizer containing ethanol, which drove us to report these cases.

Case presentation:

Case 1:

A 29-year-old male was brought to the casualty of a tertiary care center on November 2020 with complaints of diarrhea, severe vomiting, and breathing difficulty. On admission, the patient had a BP of 90/60 mmHg, pulse 100/min, and random blood glucose of 46 mg/dl. He had cold extremities, gasping respiration, and altered sensorium. He died after 6 hours of fluid resuscitation, airway maintenance, and intensive care treatment. History revealed that the deceased was an alcohol addict but, due to lockdown, had shifted toward consumption of surrogate alcohol, i.e., hand sanitizer, for 6 to 8 months. On the night before death, he consumed hand sanitizer in an unknown amount. Police found 20 empty bottles of hand sanitizer of government supply containing 70% ethanol along with some Aryurvedic content at the crime scene. The autopsy revealed a severely congested face with dried blood-tinged fluid oozing through the nostrils and mouth. The stomach contained about 100 cc of brownish fluid material.

Case 2:

A 22-year-old married female was brought to the casualty on January 2021 with complaints of severe vomiting, altered sensorium, and breathing difficulty. On admission, she was unconscious with BP 90/40 mmHg, pulse 102/min, tachypnoea, and random blood glucose 60 mg/dl. Intensive treatment could not save her life, and she was declared dead within one hour of admission. History revealed that the deceased was a rag picker and an alcohol addict, but because of the lockdown, she was consuming hand sanitizer for 4 to 5 months. The night before her death, she and her husband ingested hand sanitizer in an unknown amount. During a crime scene visit, the police found 32 bottles of hand sanitizer containing 70% ethanol (Figure 1). The autopsy revealed a severely congested face with dried blood-tinged saliva stains at the left angle of the mouth, dribbling toward the left cheek. Internally, the peritoneum was severely congested and hemorrhagic. The stomach contained 250 cc of greenish pasty material.

Case 3:

A 17-year-old unmarried male was brought to the casualty on January 21 with a complaint of diarrhea, severe vomiting, and altered sensorium. On examination, he was semiconscious, had BP 100/60 mmHg, pulse 100/min, respiratory rate 24/min, and random blood glucose 89 mg/dl. Despite intensive

care given overnight, he could not be treated and was declared dead in the early morning hours. The deceased was the brother-in-law of the female in case number 1. Female in case no. 1 and the deceased, both were consuming hand sanitizer for some time. On the night before his death, the deceased, case number 1, and the deceased's elder brother consumed hand sanitizer in an unknown amount. On autopsy, the stomach contained 100 ml of mucoid fluid material.

Case 4:

A 28-year-old married male was brought to the casualty on January 2021 with a complaint of severe vomiting. On examination, he was conscious but disoriented, had cold extremities, BP was 90/70 mmHg, pulse 100/ min, respiration 26/min, and random blood glucose 64 mg/dl. IV fluids with intensive care treatment were given for 20 hours and declared dead at night. History revealed that the deceased was the husband of the female in case number 1. Both of them have been consuming the hand sanitizer for some time, and the night before his death, he along with cases 1 and 2 consumed the hand sanitizer in an unknown amount. On autopsy, external findings were unremarkable. The stomach contained about 50 ml of mucoid fluid material.

Case 5:

A 46-year-old married male was brought to the private hospital on May 2021 with complaints of severe vomiting, diarrhea, and altered sensorium. He was in a semiconscious state, had gasping respiration, BP 90/50 mmHg, pulse 110/min, and random blood glucose 44 mg/dl. He was admitted to the intensive care unit overnight and declared dead in the early morning hours. After taking a thorough history, it was revealed that the deceased was an alcohol addict, and because of some quarrel with his wife, he drank hand sanitizer in an unknown amount. On autopsy, external findings were unremarkable. Stomach was containing 100 ml of brownish fluid material.

Case 6:

A 38-year-old married male was brought to the emergency on December 2021 with complaints of severe vomiting, diarrhea, giddiness, and breathing difficulty. He was immediately admitted to the hospital. At the time of admission, he was conscious but disoriented. His BP was 90/40 mmHg, pulse 110/min, and fast labored breathing. Prompt treatment with IV fluids, antibiotics, and inotropic support was given for 3 days. Blood work revealed high anion gap metabolic acidosis, hypoglycemia, and hypokalemia. After 72 days of intensive care treatment, he was declared dead with the diagnosis of Multiple Organ Dysfunction Syndrome (MODS) followed by acute liver failure. History revealed that the deceased was an alcohol addict. He drank the hand sanitizer in an unknown amount to win a bet. The autopsy revealed unremarkable external findings. The stomach contained about 50 ml of mucoid fluid.

Symptoms and gross autopsy findings were similar in all cases. The face, conjunctivas, brain parenchyma, peritoneum, liver, kidneys, spleen, and gastric mucosa were congested. Brain parenchyma was edematous. Peritoneum was hemorrhagic. Liver showed patchial hemorrhages and was gritty to cut. Kidneys were hemorrhagic with loss of cortico-medullary differentiation. Spleen was hemorrhagic. Gastric mucosa sloughed necrosed, along with patchy hemorrhages, and gastric mucosal rugosities were prominent. After the autopsy, viscera and blood samples preserved for chemical analysis were sent to the Forensic Science Laboratory (FSL), which were positive for ethyl alcohol in cases 1 to 5 and negative in case 6.

Histopathological Examination:

In all six cases, tissue samples were preserved and examined histopathologically. Microscopy revealed surface mucosal ulceration in the stomach and intestine (Figure 2a,). Dilated, congested, and thrombosed blood vessels in the stomach, intestine, liver, lung, spleen, kidney, heart, and brain tissue (Figure 2 to 4). Cellular infiltration in the stomach, intestine, and brain tissue (Figure 2a, c, 4e), necrosis of heart tissue (Figure 4c), focal acute tubular necrosis in kidneys (Figure 4e), and

parenchymal hemorrhages in the lung and spleen (Figure 2e, 3f), brownish hemosiderin pigments depositions in the liver (Figure 4b).

Discussion:

Although cases with intentional hand sanitizer ingestion have been previously described, here we present 6 autopsy cases of acute ingestion of high doses of hand sanitizer containing ethyl alcohol as the main constituent.

Intoxication from ethanol-based hand sanitizers can lead to serious and life-threatening adverse health effects. These include but are not limited to central nervous system and respiratory depression, cardiac dysrhythmias or arrest, nausea and vomiting, liver injury, and lactic and ketoacidosis.^[12, 13] A similar clinical findings were seen in our cases. The clinical and treatment histories of the cases were retrieved from hospital records. Since there is no specific antidote available for the treatment of acute hand sanitizer poisoning, the treatment provided was mainly symptomatic and supportive. Because of the volatile nature and acute damaging effects of the hand sanitizer, gastric lavage was not performed in any case. Case history was taken from relatives and police personnel of the concerned cases. In all the cases the amount of acute hand sanitizer consumption was unknown. In cases 2-4, on crime scene visit 32 empty sanitizer bottles containing 70% v/v ethyl alcohol per 100 ml each were found, and 20 empty bottles from case 1. (Figure 1) FSL report confirmed presence of ethyl alcohol in viscera and blood samples of diseased in case 1 to 5 and it was found negative in case 6, due to 72 hour survival time, provided that quantitative analysis is not performed in FSL. Histopathological findings of our cases strongly suggested multi-organ tissue damage.

All cases represented and confirmed the clinical pathophysiology of multi-organ dysfunction due to the ill effects of ethyl alcohol present in hand sanitizer, shedding light on an emerging problem in India among alcohol-addicted people, particularly those who belong to the lower socio-economic strata. The cases described were addicted to alcohol, and because of the lockdown started consuming hand sanitizer and continued to do so even after the lockdown had been lifted. On the night before death, they consumed a copious amount of hand sanitizer, on common and separate occasions, which resulted in death.

Due to easy availability and lower cost, alcohol-addicted people are becoming addicted to the hand sanitizer; thus, the government should consider the possibility and exercise caution in distributing hand sanitizer. The masses should also be educated regarding the 'not to drink' hand sanitizer in place of alcohol. There are not many studies on this topic, and hence, the data are limited. The need of the hour is that more studies should be conducted so that preventive strategies can be formed.

Figure Legends:

Figure 1: Photograph showing sanitizer bottle retrieved from the crime scene (a) Case 2, 3 and 4, the constituents of the compound present inside (b), congested and edematous lung and liver with patchial hemorrhages on the surface (c) Stomach showing congested mucosa with multiple hemorrhagic areas (d).

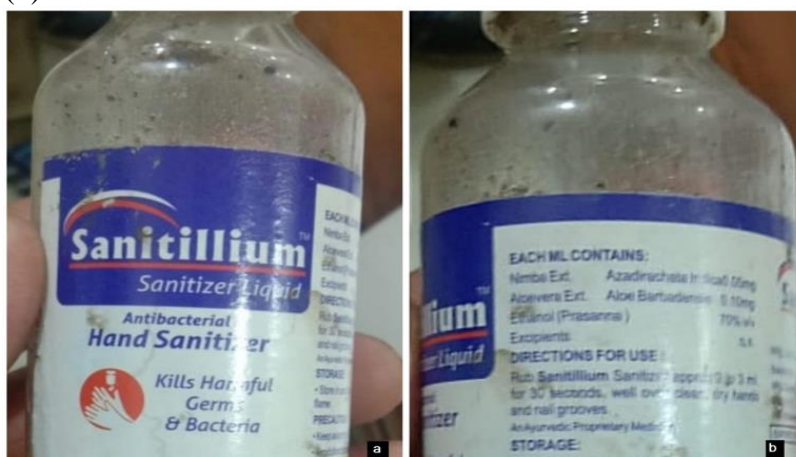

Figure 2: Photo-micrograph of Stomach tissue showing surface mucosal ulceration with chronic mucosal cellular infiltrates. 4X (a), congested & thrombosed blood vessel in serosa, 4X (b), Intestinal tissue showing thrombosed congested blood vessel and chronic cellular infiltration at 10X (c). Lung tissue showing alveolar edema. 4X (d), and diffuse parenchymal hemorrhage 10X (e), dilated, congested and thrombosed blood vessel 10X (f).

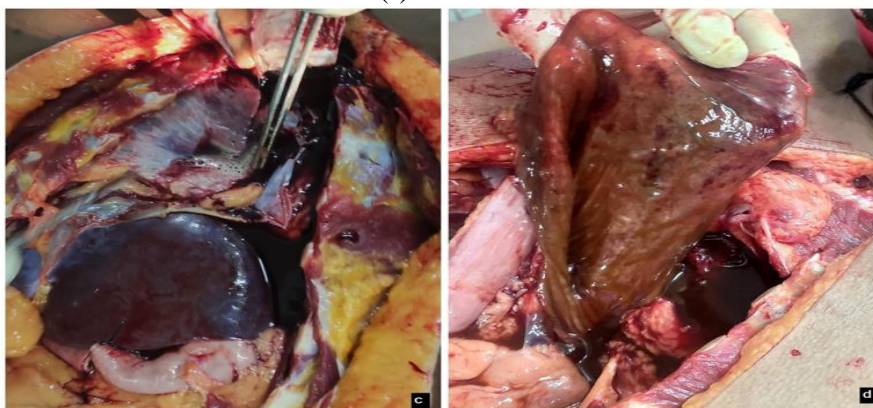


Figure 3: Photomicrograph showing Kidney tissue having thrombosed dilated blood vessels. 4X (a), congested renal tubules. 4X (b), congested tubules. 10X (c), thrombosed dilated blood vessel. 4X (d), congested tubules & focal acute tubular necrosis. 10X (e), and spleen tissue showing parenchymal hemorrhage. 10X (f).

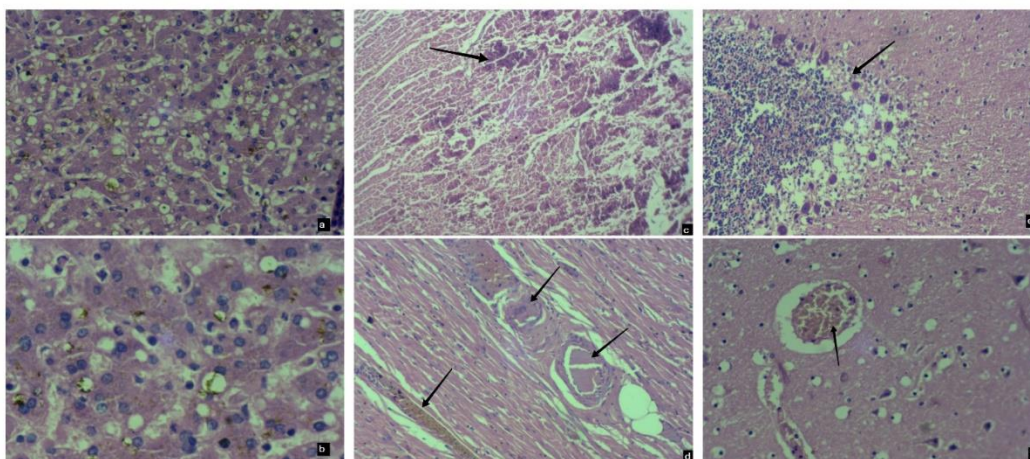
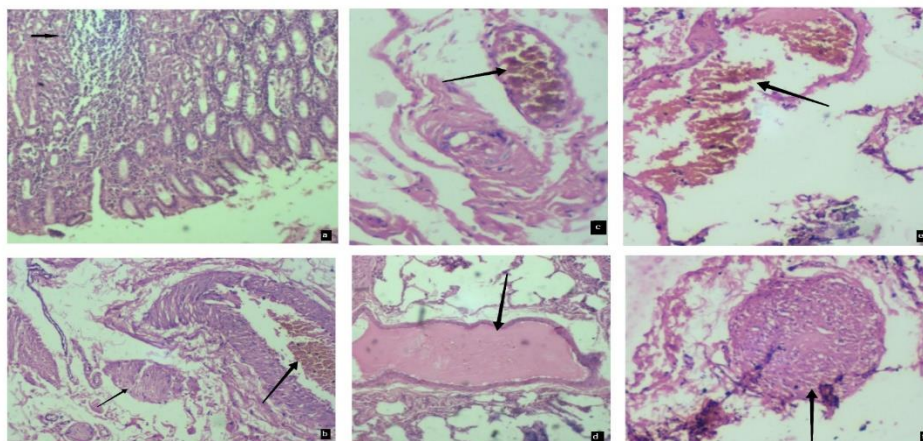


Figure 4: Photomicrograph of Liver tissue showing hemosiderin deposition along with ballooning of hepatocytes, 20X (a), and hemosiderin deposition 40X (b). Heart tissue showing necrosis. 4X (c) and thrombosed congested blood vessel 20X (d). Brain tissue showing cellular infiltrates 10X (e), and congested, thrombosed blood vessel 20X (f).



References:

1. Bolon MK. Hand hygiene: An update. *Infect Dis Clin North Am* [Internet]. 2016;30(3):591–607. Available from: <http://dx.doi.org/10.1016/j.idc.2016.04.007>
2. Mayhall G. *Hospital epidemiology and infection control*. 2nd ed. Philadelphia, PA: Lippincott Williams and Wilkins; 1999.
3. Firstcoastnews.com. [cited 2023 Apr 27]. Available from: <http://www.firstcoastnews.com/news/health/news-article.aspx?storyid=84913>
4. Gormley NJ, Bronstein AC, Rasimas JJ, Pao M, Wratney AT, Sun J, et al. The rising incidence of intentional ingestion of ethanol-containing hand sanitizers. *Crit Care Med* [Internet]. 2012;40(1):290–4. Available from: <http://dx.doi.org/10.1097/CCM.0b013e31822f09c0>
5. BBC news. BBC [Internet]. [cited 2023 Apr 27]; Available from: http://news.bbc.co.uk/2/hi/uk_news/england/dorset/8272799.stm
6. Rabin RC. Don't Drink the Hand Sanitizer. *The New York times* [Internet]. 2016 Oct 24 [cited 2023 Apr 27]; Available from: <https://www.nytimes.com/2016/10/24/well/live/dont-drink-the-hand-sanitizer.html>
7. Crescioli G, Lanzi C, Gambassi F, Ieri A, Ercolini A, Borgioli G, et al. Exposures and suspected intoxications during SARS-CoV-2 pandemic: preliminary results from an Italian poison control centre. *Intern Emerg Med* [Internet]. 2021; Available from: <http://dx.doi.org/10.1007/s11739-021-02774-0>
8. Karimi F. Three people died and one is permanently blind after drinking hand sanitizer in New Mexico. *CNN* [Internet]. 2020 Jun 27 [cited 2023 Apr 27]; Available from: <https://www.cnn.com/2020/06/27/us/new-mexico-hand-sanitizer-deaths-trnd/index.html>
9. Yip L, Bixler D, Brooks DE, Clarke KR, Datta SD, Dudley S Jr, et al. Serious adverse health events, including death, associated with ingesting alcohol-based hand sanitizers containing methanol - Arizona and New Mexico, May-June 2020. *MMWR Morb Mortal Wkly Rep* [Internet]. 2020;69(32):1070–3. Available from: <http://dx.doi.org/10.15585/mmwr.mm6932e1>
10. Pratap RM, Guy J. Indian children hospitalized after ingesting hand sanitizer instead of polio drops. *CNN* [Internet]. 2021 Feb 2 [cited 2023 Apr 27]; Available from: <https://www.cnn.com/2021/02/02/asia/india-children-hospitalized-sanitizer-scli-intl/index.html>
11. Kuehn BM. Hand sanitizer poisoning and deaths reported in 2 states. *JAMA* [Internet]. 2020 [cited 2021 Dec 30];324(12):1130. Available from: <https://jamanetwork.com/journals/jama/fullarticle/2770868>
12. Vonghia L, Leggio L, Ferrulli A, Bertini M, Gasbarrini G, Addolorato G: Acute alcohol intoxication. *Eur J Intern Med*. 2008, 19:561-7. 10.1016/j.ejim.2007.06.033
13. LaHood AJ, Kok SJ. Ethanol Toxicity. [Updated 2023 March 13]. In: *StatPearls* [Internet]. Treasure Island (FL): StatPearls Publishing;2023 Jan.

Acknowledgement: We Acknowledge Dr Sneha Chaubal, Senior Pathologist, and Dr Upasana Unia, Assistant Professor, Department of Pathology, Gandhi Medical College, Bhopal, for her contribution in processing the tissue samples and verifying microscopic findings and providing photomicrographs of specific histological findings.